

Incidental skeletal abnormalities in a 22-year-old man

WILLIAM J. BUFKIN, MD

A 22-year-old man presented to the emergency department because of trauma. Radiographic images are shown below (Figures 1–3).

For diagnosis and discussion, see the following page.

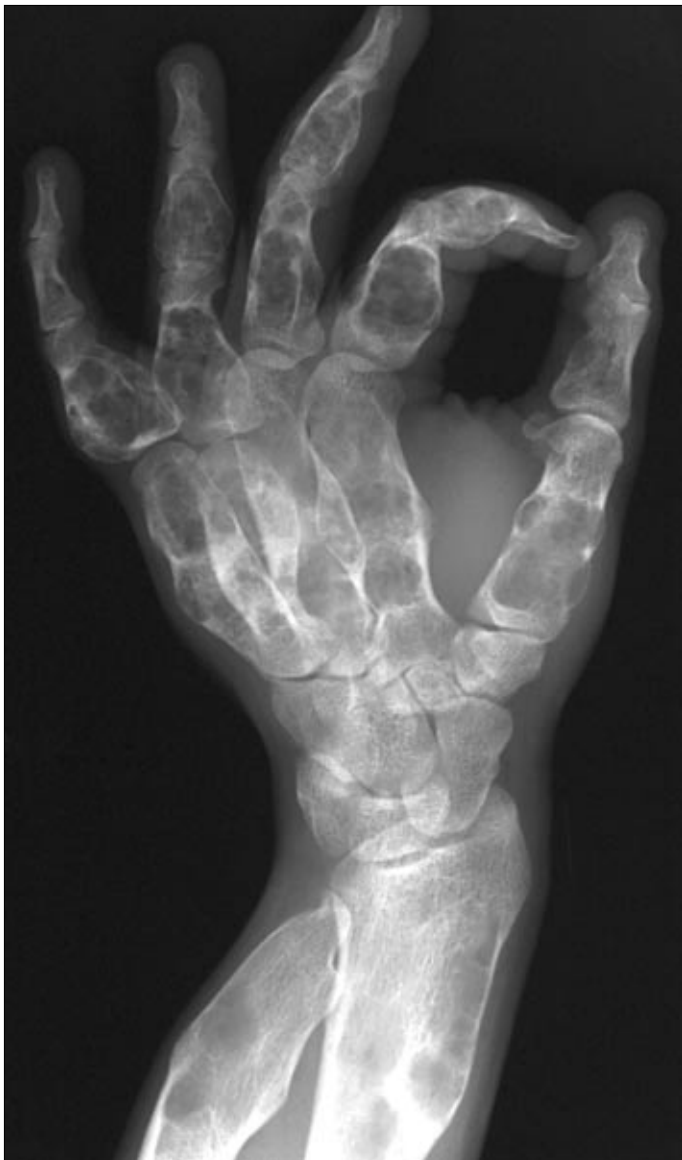


Figure 1. Oblique radiograph of the hand and wrist demonstrates multiple radiolucent, expansile masses of varying shapes in the phalanges, metacarpals, radius, and ulna.

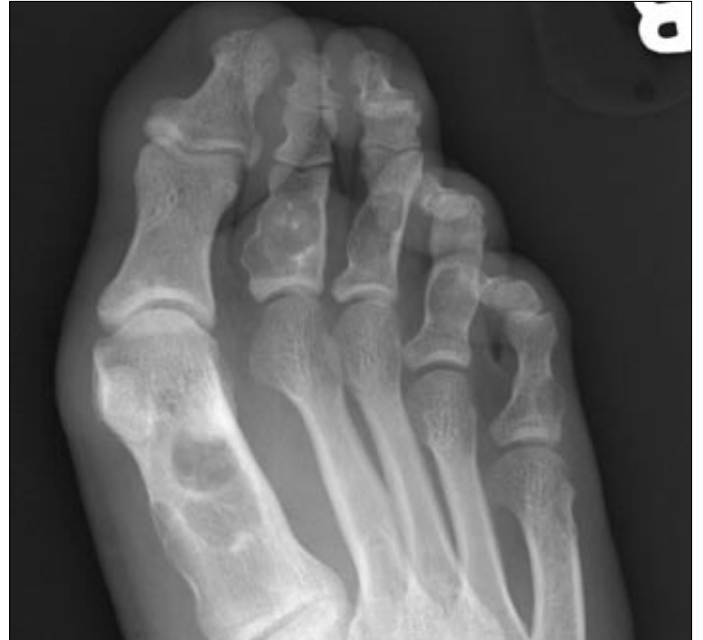

Figure 2. Anteroposterior radiograph of the foot demonstrates similar lesions in the first metatarsal and in multiple phalanges.

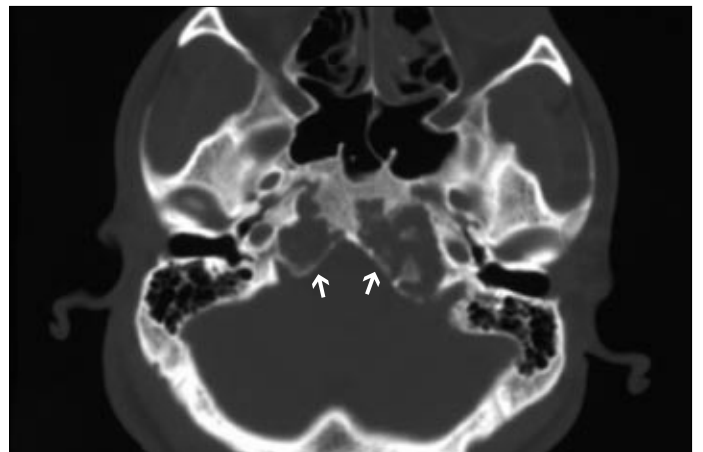


Figure 3. Axial computed tomography (CT) image of the skull base shows an expansile, cartilaginous mass (arrows) involving the parasellar area and petrous apices.

From the Department of Radiology, Baylor University Medical Center, Dallas, Texas.

Corresponding author: William J. Bufkin, MD, Pueblo Radiological Group, PC, 124 West Pitkin Avenue, Pueblo, Colorado 81004.

DIAGNOSIS: Enchondromatosis (Ollier's disease).

DISCUSSION

Enchondromatosis, or Ollier's disease, is a rare, nonhereditary dyschondroplasia characterized by multiple, asymmetrical enchondromas throughout the skeleton. The lesions occur in both the tubular and the flat bones and may be intraosseous or subperiosteal. The tibia, femur, and fibula are most frequently involved (1). Histologically, enchondromatosis is a disorder of enchondral ossification. Round or columnar masses of unossified hyperplastic cartilage are present in the metaphyses, and these sometimes extend into the diaphysis (2).

Although the lesions can be demonstrated radiographically in infancy, the clinical manifestations of the disease usually appear during the first decade of life. The usual presenting findings are palpable bony masses that increase in size as the child grows and asymmetric shortening of the extremities. This asymmetric shortening is usually produced by extension of an asymmetrical metaphyseal lesion into the physis. Osseous deformities may also be secondary to pathologic fractures, and these are also most common in the femur. Stabilization or regression of the lesions usually occurs in adulthood. Enlargement of a lesion in the adult usually indicates malignant transformation. By age 40, malignant transformation occurs in approximately 25% of patients.

The characteristic radiographic findings are masses of hyaline cartilage within the medullary cavity that may be round, triangular, or linear. Focal areas of calcification are frequently present within the masses. In the tubular bones, the lesions are usually expansile, and this is typically most pronounced in the hands. The condition has a strong preference for unilateral involvement.

Magnetic resonance (MR) imaging demonstrates the enchondromas to be well-delineated, lobulated masses that have low signal intensity on T1-weighted images and high signal intensity on T2-weighted images (Figure 4).

A similar rare condition, Maffucci's syndrome, is manifested by enchondromas and soft tissue vascular lesions. Maffucci's syndrome is congenital, nonhereditary, and usually diagnosed at birth or during the first decade of life. The soft tissue abnormalities in Maffucci's syndrome are usually cavernous or capillary hemangiomas and, less frequently, lymphangiomas and epithelioid hemangioendotheliomas. These vascular lesions vary in number and may become large. The hands are frequently severely involved, as shown in Figure 5.

The distribution of the osseous and soft tissue vascular lesions is usually, but not always, similar. Hemangiomas located in the head and neck may deform the trachea and may cause dysphagia or epistaxis. The mucous membranes or other organs, including the gastrointestinal tract, may also be involved. Large hemangiomas can interfere with normal bone growth and can result in scoliosis. Maffucci's syndrome is associated with a higher frequency of malignant transformation of the enchondromas than is Ollier's disease. Although the risk of malignant transformation is greater for the skeletal lesions, hemangiosarcomas, lymphangiosarcomas, and fibrosarcomas may result from malignant transformation of the soft tissue lesions.

The radiographic findings in Maffucci's syndrome are similar to the findings in Ollier's disease, with the addition of soft tissue masses that frequently contain phleboliths and a variable amount

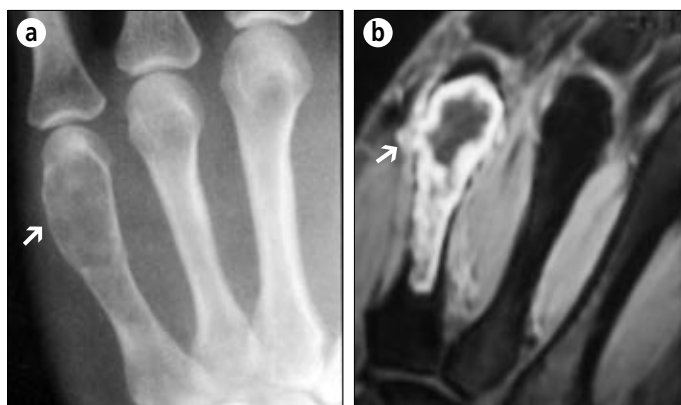

Figure 4. (a) Radiograph of the hand shows an expansile, intramedullary lesion (arrow) in the distal metacarpal that has eroded the endosteal margin of the cortex. (b) Coronal T2-weighted MR image of the hand demonstrates a lobulated, endosteal mass that has eroded and penetrated the endosteal cortex (arrow). (Courtesy of Karl A. Glastad, MD.)

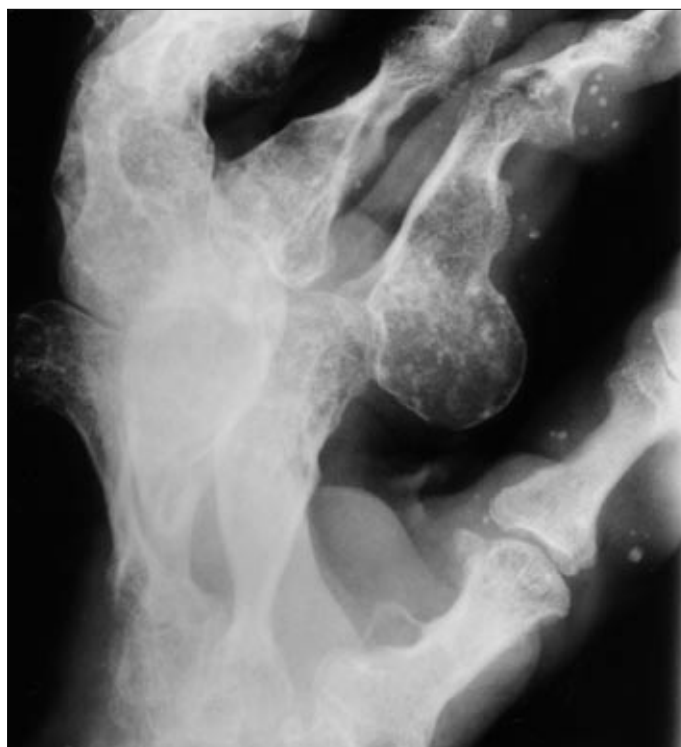


Figure 5. Maffucci's syndrome. Radiograph of the hand shows enchondromas in every bone and soft tissue masses that contain phleboliths. (Courtesy of Guerdon D. Greenway, MD.)

of calcification (Figure 5). CT and MR imaging are frequently useful in the evaluation of both the bony and soft tissue lesions (3).

1. Resnick D, Kyriakos M, Greenway GD. Tumors and tumor-like lesions of bone: imaging and pathology of specific lesions. In Resnick D, ed. *Diagnosis of Bone and Joint Disorders*, 4th ed, vol 4. Philadelphia: WB Saunders Co, 2002: 3833–3848.
2. Mainzer F, Minagi H, Steinbach HL. The variable manifestations of multiple enchondromatosis. *Radiology* 1971;99:377–388.
3. McAlister WH, Herman TE. Osteochondrodysplasias, dysostoses, chromosomal aberrations, mucopolysaccharidoses, and mucopolipidoses. In Resnick D, ed. *Diagnosis of Bone and Joint Disorders*, 4th ed, vol 5. Philadelphia: WB Saunders Co, 2002:4502–4503.