

Acute gastric dilation and ischemia secondary to small bowel obstruction

Shawn Steen, MD, Jeffrey Lamont, MD, and Laura Petrey, MD

Acute gastric dilation leading to ischemia of the stomach is an underdiagnosed and potentially fatal event. Multiple etiologies can lead to this condition, and all physicians should be aware of it. Without proper and timely diagnosis and treatment, gastric perforation, hemorrhage, and other serious complications can occur. We report a case of acute gastric dilation and ischemia secondary to small bowel obstruction. We also review the world literature and discuss the etiology, diagnosis, and management of this condition.

A 71-year-old man presented with a 1-day history of diffuse unrelenting abdominal pain associated with emesis and abdominal distention. He had an episode of small bowel obstruction 5 months prior to presentation that was treated nonoperatively. His past medical history was significant for hypertension, nephrolithiasis, and an inguinal hernia repaired when he was a child. The initial physical examination revealed a distended abdomen tympanic to percussion in the left upper quadrant but without peritoneal signs. An abdominal radiograph showed dilated small bowel loops with a diffuse opacity in the left upper quadrant. On admission, his white blood cell count was $15 \times 10^3/\mu\text{L}$ with 10% bands and a serum lactate of 7.5 mmol/L (reference range, 0.5–2.2). An arterial blood gas analysis showed a bicarbonate level of 19 mEq/L with a base deficit of -7 . A computed tomography (CT) scan revealed complete small bowel obstruction with a transition point in the distal ileum, associated pneumatosis intestinalis of the ileum, and emphysematous gastritis with air at the gastroesophageal junction and in the portal vein (*Figures 1 and 2*).

The patient was resuscitated with intravenous fluids and taken emergently to the operating room, where a midline laparotomy was performed. The small bowel was distended but viable. A single adhesion in the right lower quadrant causing torsion of the small bowel was released, but no other points of obstruction were found. A nasogastric tube was placed in the emergency department but did not function until it was repositioned in the operating room. Five liters of brown gastric content were suctioned from the nasogastric tube in the operating room. After decompression of the largely distended stomach, patchy areas of dark ischemic tissue along the greater curve

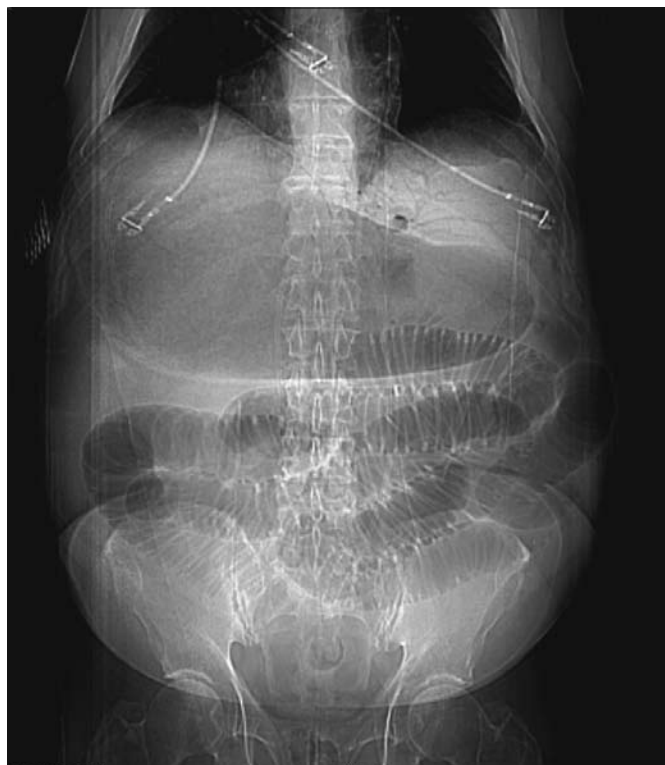

Figure 1. CT scout image showing massive gastric dilation.

of the stomach were noted. No full-thickness perforation was identified. An intraoperative esophagogastroduodenoscopy was performed that revealed severe esophagitis, as well as patchy areas of mucosal ischemia along the entire body and greater curve of the stomach. Good Doppler signals were found along the left and right gastric arteries and along the short gastric vessels. It was decided to pack the abdomen and close with a wound vacuum-type dressing and return to the operating room in 24 hours for a second look.

The patient was packed open and taken to the intensive care unit for resuscitation. His base deficit corrected over the next

From the Department of Surgery, Baylor University Medical Center, Dallas, Texas.

Corresponding author: Shawn Steen, MD, Department of Surgery, Baylor University Medical Center, 3500 Gaston Avenue, Dallas, Texas 75246 (e-mail: ShawnSteen@BaylorHealth.edu).

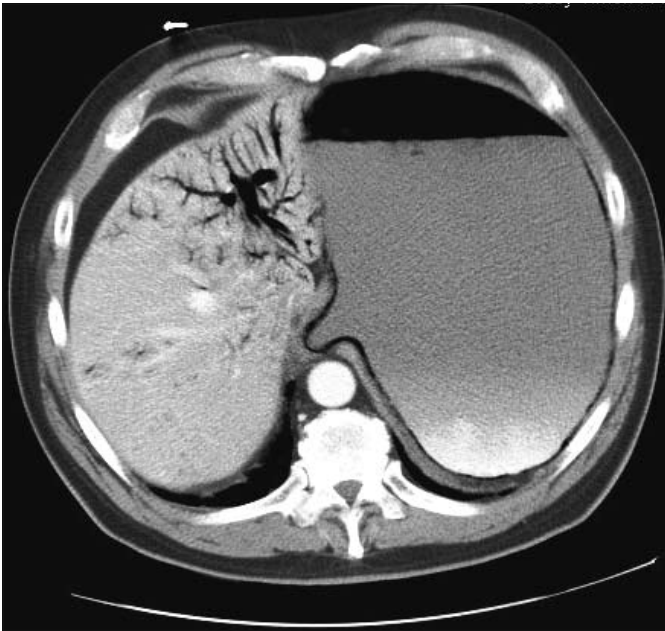


Figure 2. CT image with gastric dilation and portal venous air.

few days. Two more “second-look” procedures were undertaken on postoperative days 1 and 3, along with repeat esophagogastroduodenoscopies (*Figure 3*).

During subsequent operations the mucosa looked viable with some residual sloughing. No further distension of either the small bowel or stomach was noted. No full-thickness ischemia or perforation was identified. The fascia was closed, and a nasojejunal feeding tube was placed during the third operation. A CT angiogram was done after the initial operation that showed a suspected stenosis at the origin of the celiac artery with mild poststenotic dilation. The superior and inferior mesenteric arteries were without stenosis. Vascular consultation concluded that invasive therapy was not indicated, as the patient was recovering well and had intact collateral flow. The patient eventually recovered and was discharged on day 21 tolerating an oral diet.

DISCUSSION

Acute gastric dilation is described in the literature as a result of eating disorders, trauma resuscitation, volvulus of hiatal hernias, medications, electrolyte abnormalities, psychogenic polyphagia, superior mesenteric artery syndrome, and a myriad of other conditions (1–5). Acute gastric dilation was first described by S. E. Duplay in 1833 (4). Although rare, it can have devastating consequences. Gastric ischemia and perforation as a result of dilation has a reported mortality rate of 80% to 100% (5).

It is rare to have ischemic events in the stomach due to its copious collateral circulation. Ischemia in the case of gastric dilation is postulated to be due to venous insufficiency (4, 6, 7). The pressure in the stomach lumen must be >14 mm Hg to exceed gastric venous pressure and lead to ischemia (1, 4). As little as 3 L of fluid can distend a normal stomach to this point of tension (6). The chronicity of stomach dilation is also a factor. Gastric volumes as high as 15 L have been recorded in certain eating disorders such as psychogenic polyphagia and bulimia.

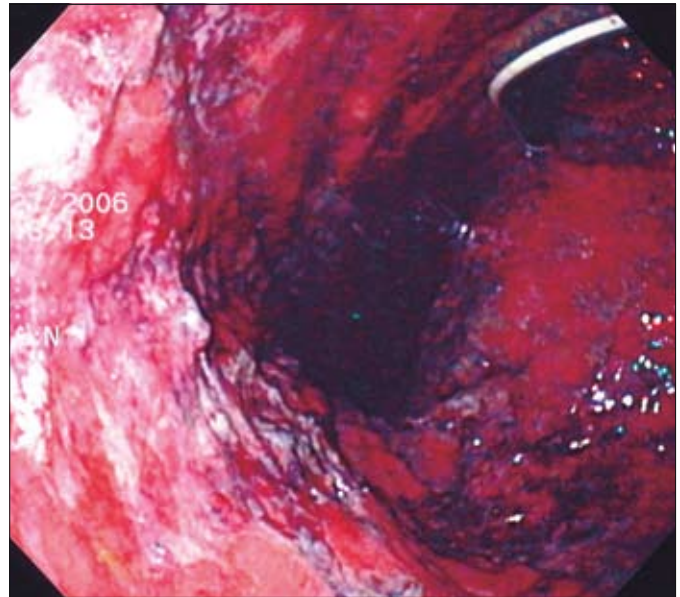


Figure 3. Esophagogastroduodenoscopy picture showing mucosal ischemia.

Gastric rupture can occur with an intragastric pressure of 120 to 150 mm Hg, which can occur with only 4 L of fluid in a normal stomach (8). Rupture can also occur if external compression is added, such as cardiopulmonary resuscitation (8).

Symptoms of acute gastric dilation can be initially vague. Emesis is common and occurs in >90% of cases (1). Progressive abdominal distention and accompanying pain are common but may initially be deceptively mild (1). Symptoms become much more marked if perforation results (2). With perforation, peritoneal signs usually are present. Irritation of the peritoneal cavity can lead early on to a profound vagal response resulting in neurogenic shock and later to true septic shock (6). Cases have been reported in which blood flow from the aorta is blocked by compression from a massively dilated stomach (9, 10). In the case of impaired blood flow to organs and limbs, decompression of the stomach can lead to acute cardiac decompensation from a sudden return of lactic acid and decreased afterload (10). A “staged decompression” to prevent these sequela has been suggested (10). Delayed gastric hemorrhage after decompression has also been reported (10).

Imaging is a key factor in diagnosis. Either plain radiographs or CT scans will reveal a massively dilated stomach. CT is a more accurate method of identifying associated causes of acute gastric dilation.

Treatment focuses on early diagnosis and decompression of the stomach, thus halting the vascular congestion and ensuing ischemia (7). Delayed perforation or bleeding is still possible, even after decompression. Endoscopy in the stable patient may be of use—particularly if the CT scan suggests gastric or esophageal involvement. Most reports on acute gastric dilation note that the majority of ischemic changes occur along the greater curve of the stomach (3). The lesser curvature and pyloric regions of the stomach tend to be spared (1). Surgical exploration is mandated in the presence of instability or other indications, such as associated small bowel obstruction or ischemia of the small bowel.

The surgical approach depends on the extent of ischemia, the presence of frank necrosis, and current or impending gastric wall perforation. Surgical resection of the gangrenous portion of the stomach is critical. Techniques that include total gastrectomy with either esophagojejunostomy reconstruction in a stable patient or esophagostomy in an unstable patient have been performed (1). A feeding jejunostomy is a critical portion of the procedure (1). Other authors have discussed successful nonoperative therapy and even partial resections or local debridement (4, 11). Many argue that if any surgical resection is needed, total gastrectomy is the safest option. Proponents of surgical resection cite delayed ischemia and poor healing of gastric tissue left behind. Overall, the surgical mortality rate has been described as 50% to 80% (1, 2). Without appropriate treatment, gastric ischemia is uniformly fatal.

In our case of acute gastric dilation secondary to a small bowel adhesive obstruction, the gastric distension of approximately 5 L of fluid seems to have led to gastric wall ischemia from venous congestion—in concurrence with reports in the literature. The arterial blood flow to the stomach was intact based on intraoperative findings and radiographic tests. Also, as commonly reported in the literature, the ischemia was largely located along the greater curve of the stomach. This patient was managed without gastric tissue resection. The importance of early diagnosis and appropriate management of acute gastric necrosis is demonstrated.

1. Todd SR, Marshall GT, Tyroch AH. Acute gastric dilatation revisited. *Am Surg* 2000;66(8):709–710.
2. Liu TH, Mehall JR, Mercer DW. Image of the month. Acute gastric dilation with necrosis. *Arch Surg* 2001;136(12):1437–1438.
3. Lunca S, Rikkers A, Stanescu A. Acute massive gastric dilatation: severe ischemia and gastric necrosis without perforation. *Rom J Gastroenterol* 2005;14(3):279–283.
4. Powell JL, Payne J, Meyer CL, Moncla PR. Gastric necrosis associated with acute gastric dilatation and small bowel obstruction. *Gynecol Oncol* 2003;90(1):200–203.
5. Koyazounda A, Le Baron JC, Abed N, Daussy D, Lafarie M, Pinsard M. Gastric necrosis caused by acute gastric dilatation. Total gastrectomy. Recovery [article in French]. *J Chir (Paris)* 1985;122(6–7):403–407.
6. Sinicina I, Pankratz H, Buttner A, Mall G. Death due to neurogenic shock following gastric rupture in an anorexia nervosa patient. *Forensic Sci Int* 2005;155(1):7–12.
7. Baldassarre E, Capuano G, Valenti G, Maggi P, Conforti A, Porta IP. A case of massive gastric necrosis in a young girl with Rett syndrome. *Brain Dev* 2006;28(1):49–51.
8. Lin PY, Tsai MS, Chang JH, Chen WJ, Huang CH. Gastric distension: a risk factor of pneumoperitoneum during cardiopulmonary resuscitation. *Am J Emerg Med* 2006;24(7):878–879.
9. Gyurkovics E, Tihanyi B, Szijarto A, Kaliszky P, Temesi V, Hedvig SA, Kupcsulik P. Fatal outcome from extreme acute gastric dilation after an eating binge. *Int J Eat Disord* 2006;39(7):602–605.
10. Lewis S, Holbrook A, Hersch P. An unusual case of massive gastric distension with catastrophic sequelae. *Acta Anaesthesiol Scand* 2005;49(1):95–97.
11. Arenal Vera JJ, Cendoya Ansola I, Alvarez Cuesta LJ, Muniesa Soriano JA. Necrosis of the greater curvature following acute dilatation of the stomach [article in Spanish]. *Rev Esp Enferm Dig* 1991;80(6):405–407.